

# Patterns of Disease and Culture in Ancient Panama: A Bioarchaeological Analysis of the Early Graves at Cerro Juan Díaz

Nicole E. Smith-Guzmán,<sup>a,b\*</sup> Luis A. Sánchez Herrera,<sup>c</sup> and Richard G. Cooke<sup>a,b</sup>

<sup>a</sup>Smithsonian Tropical Research Institute, Panama, Republic of Panama

<sup>b</sup>Sistema Nacional de Investigación, Secretaría Nacional de Ciencias y Tecnología, Panama, Republic of Panama

<sup>c</sup>Departamento de Antropología e Historia, Museo Nacional de Costa Rica, San José, Costa Rica

\*Correspondence to: Nicole Smith-Guzmán, Smithsonian Tropical Research Institute, Ancon, Panama City, A.P. 0843-03092, Republic of Panama.  
e-mail: smithn@si.edu

**ABSTRACT:** Cerro Juan Díaz (LS-3) is a large archaeological site located in the coastal lowlands of central Pacific Panama that comprised a pre-Columbian village (200 B.C.–A.D. 1520). A multiyear field campaign (1992–2001) uncovered numerous human burials of diverse antiquity, integrity, complexity, and mortuary goods. This paper considers several aspects of the demography, diet, health, and cultural practices of the earliest mortuary population yet found at LS-3 (A.D. 30–650) through the analysis of human skeletal remains found in the excavation of Operation 3, Features 1, 2, 16, and 94. This research has led to revised interpretations of these important mortuary contexts. Many of the personal adornments traditionally placed at the apex of regional value systems were found with the remains of children, giving support to the notion that, during this time period, age was the primary determinant of the kinds of ornaments that accompanied the dead. Oral pathologies present signal the importance of cariogenic foods, such as maize, in the diet, while lingual surface attrition of the maxillary anterior teeth points to a habitual cultural practice of using the teeth as tools—perhaps to peel manioc tubers prior to cooking. Head shaping appears to have been an important identity marker in the population, with high frequencies of obelionic-type artificial cranial modification. Participation in a male-dominated habitual aquatic activity is revealed by external auditory exostoses in several individuals. Finally, a systemic infection consistent with *Treponema pallidum* was prevalent in the population, as evidenced by characteristic osseous lesions.

**Keywords:** paleopathology; Central America; Isthmo-Colombian Area

Cerro Juan Díaz (LS-3) es un sitio arqueológico en la llanura costera del Pacífico central de Panamá que fungió como aldea precolombina desde 200 a.C. hasta 1520 d.C. Durante campañas de campo que se extendieron por diez años (1992–2001), se descubrió numerosos entierros humanos cuya antigüedad, integridad y complejidad, así como sus ajueros mortuorios, eran disímiles entre sí. El presente artículo adopta un enfoque bioarqueológico con el fin de dilucidar varios aspectos de la demografía, la dieta, la salud y las prácticas culturales de la población mortuoria más antigua que se haya encontrado hasta la fecha en el asentamiento (30–650 d.C.). Nos concentramos en el análisis de los restos humanos correspondientes a las sepulturas más antiguas excavadas en el sitio: Rasgos 1, 2, 16 y 94 de la Operación 3. Dicho estudio conllevó a revisar interpretaciones anteriores de estos importantes contextos mortuorios. Algunos adornos personales que suelen colocarse en el ápice del sistema de valores a nivel regional se encuentran con niños y dan apoyo a propuestas anteriores de que, en esta

época, la edad de un difunto era el principal determinante de los bienes que lo acompañaban en la muerte. Las patologías orales presentes incluso en niños pequeños en el sitio señalan la importancia de alimentos cariogénicos como el maíz en la dieta, mientras que el desgaste de la superficie lingual de los dientes anteriores superiores (“LSAMAT,” por sus siglas en inglés) en muchos individuos apunta a la práctica cultural habitual de utilizar los dientes como herramienta, tal vez para pelar tubérculos como la yuca antes de cocinarlos. En esta población, la forma de la cabeza parece haber sido un importante marcador de identidad, de acuerdo con las altas frecuencias de modificación craneal artificial de tipo obeliónico, las que se observaron entre los cráneos hallados en estos entierros. Por otro lado, una consuetudinaria actividad acuática es indicada por la presencia de exostosis auditiva externa en varios individuos, mayormente masculinos. Finalmente, destaca en esta población una infección sistémica compatible con *Treponema pallidum*, tal y como lo evidencian las características lesiones óseas.

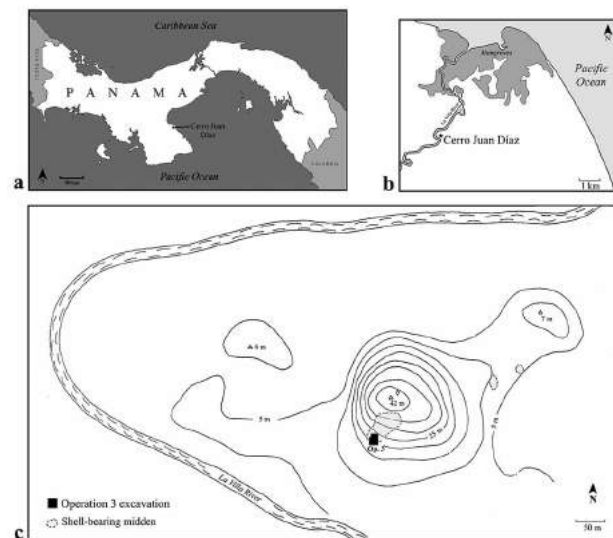
Cerro Juan Díaz (LS-3) comprises a multicomponent pre-Columbian village site straddling the La Villa River, which separates the Los Santos and Herrera provinces in central Pacific Panama (Fig. 1). Excavations supervised by Richard Cooke and led by various archaeologists took place at the site between 1992 and 2001 and sought to stem looting activities at the site and understand the chronology, subsistence economy, and cultural aspects of its ancient occupation (Cooke and Sánchez Herrera 1997; Cooke et al. 1998).

This paper concentrates on Operation 3, a 12 × 20 m excavated area of the site located on an anthropogenic platform on the southern slope of the 42-m high eponymous hill and excavated during the 1992–1995 field seasons (Sánchez Herrera 1995; Fig. 2). Here, a unique circular arrangement of 12 oval stone-lined pits was uncovered (Cooke and Sánchez Herrera 1997; Cooke et al. 1998; Cooke et al. 2000; Sánchez Herrera 1995). These pit features average 3 m in length and 2–2.5 m in depth and were constructed about A.D. 580–647<sup>1</sup> (Cooke and Sánchez Herrera 1997; Sánchez Herrera 1995). Nearly all of the pits were vandalized at some time. In the space within the circle of pits, two smaller circular features (Features 7 and 8) were placed, which could correspond to burial features, but were also looted in their entirety prior to excavation. Local people who visited the site during the excavations claimed that goldwork was taken from the vandalized features and sold.

The proximity of the stone-lined pits to the central burial features with which they are coeval (i.e., Features 7 and 8), as well as the copious wood charcoal and ash they contained, led Cooke and colleagues

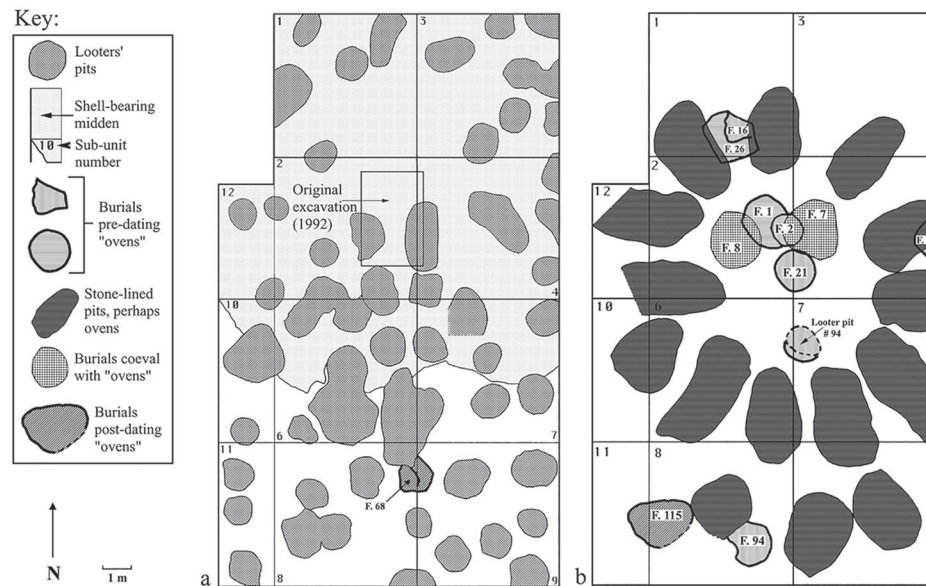
(1998) to surmise that their function may correspond to a mortuary activity similar to smoke embalming reported on the eve of conquest further east in Darién. According to Spanish chroniclers, the corpses of high-ranked ancestors were suspended over a low flame until dried, and were later displayed in mortuary houses (Espinosa 1994:63–64; Martyr d’Anghera 1912:219–220). As far as the authors are aware, no similar stone-lined pits have been found within the Isthmo-Colombian Area.

A total of eight features demonstrated or inferred to have been used for human burials were recorded under the stone-lined pits, thus predating them: Features 1, 2, 16, 17, 21, 26, and 94, as well as a feature completely disturbed by “Looter’s pit 94.” These burial features comprise some of the earliest intact contexts at the site (ca. 200 B.C.–A.D. 700). Four of these pertain to complex and often commingled burials that contained preserved human remains: Features 1, 2, 16, and 94. Although previous studies have analyzed



**Figure 1.** Maps of Cerro Juan Díaz showing the geographic location of the site (a) within Panama, (b) in relation to the La Villa River and the Pacific coast, and (c) the location of the Operation 3 excavation on the southern slope of the hill. Maps by Nicole Smith-Guzmán, modified from Smith-Guzmán and Cooke 2018a: Fig. 1 (inset a); Cooke et al. 1998: Fig. 1 (inset b); and Sánchez Herrera 1995: Fig. 3 (inset c).

<sup>1</sup> This estimated date range is based on the combination of the 2σ IntCal20 recalibrated ranges of the earliest (I-18672, 1560 ± 80 B.P., cal A.D. 265–647) and latest (I-18671, 1330 ± 80 B.P., cal A.D. 580–885) radiometric dates of charcoal samples taken from the compact clay interspersed in the stone-lined profiles from these features (Cooke and Sánchez Herrera 1997; Sánchez Herrera 1995). Further support for this estimated range comes from the absence of Conte style pottery (ca. A.D. 700–1000) within these features (Cooke 2011; Cooke and Sánchez Herrera 1997:73).



**Figure 2.** Plans of the Operation 3 excavation at Cerro Juan Díaz showing (a) widespread disturbance of the excavated area by looters' pits of varying depths, and (b) archaeological features, including those mentioned in the present paper as well as later features which often overlap these. Modified from Cooke and Sánchez Herrera 1997: Fig. 2.

these features by focusing on the unique material culture items within these burial contexts (Cooke et al. 1998; Cooke et al. 2000; Cooke et al. 2003), the results of the recently completed full analysis of the human remains reveal that individuals of all ages and sexes were buried at this location, and that specialty grave goods may relate to age rather than occupation. Evidence of perimortem trauma consistent with the interpersonal violence documented in Spanish chronicles was notably absent, but dental and skeletal pathology indicate that oral health problems and physiological stress were common. Finally, activities such as diving, craft production, and cranial modification provide insight into the lives of the ancient isthmians. The present study reports these new data and their significance from a biocultural perspective, which have revised certain previous interpretations of these important burial features.

### The Archaeological Context

The LS-3 site was occupied continuously from about 200 B.C. to the time of Spanish contact in the early sixteenth century (Isaza Aizpurúa 2007). The site is centered on a prominent hill along the south bank of the La Villa River, approximately 5 km from the current position of the active shoreline of Parita Bay in the Pacific Ocean. Extensive archaeological surveys suggest that at its apogee, LS-3 encompassed an estimated area of 150 ha, extending to the north bank of

the La Villa River and including two additional hills: Cerro Juan Gómez and Cerro Tello (Isaza Aizpurúa 2007, 2013).

In addition to its prominent funerary components, burnt clay floors with postholes and several shell-bearing middens containing faunal remains are interpreted as dwellings and domestic refuse used from about A.D. 400 to 800 (Isaza Aizpurúa 2007; Sánchez Herrera 1995). The contents of the middens suggest residents were consuming mollusks, mostly marine and occasional freshwater fish, maize, and diverse terrestrial fauna, including iguanas, birds, deer, and small mammals (Cooke and Jiménez 2008; Cooke et al. 2007; Isaza Aizpurúa 2007; Jiménez and Cooke 2001). Specific structures and features at the site have also provided evidence of craft production during the Cubitá phase (Mayo and Cooke 2005) and the conspicuous manipulation of human remains after death (interpreted as "ritual activities") during the later phases of the site's use (Carvajal et al. 2006). It is uncertain exactly how many people lived at Cerro Juan Díaz at any one time during its long occupation, but the population size likely waxed and waned, with population estimates for the La Villa River Valley reaching a maximum of 6,500 individuals during the Conte ceramic phase (A.D. 700–1000) (Isaza Aizpurúa 2007).

Cerro Juan Díaz began to be used as a mortuary center at the end of the La Mula ceramic phase (200 B.C.–A.D. 250), as shown by the earliest radiocarbon date yielded from human dentin collagen (cal A.D. 33–244; Table 1). The early burials discussed herein

date between A.D. 30 and 650 and all follow a common pattern of burial context reuse (Cooke et al. 2000). Old burials were repeatedly disturbed in antiquity and their contents rearranged to accommodate new occupants. Primary burials are rare while secondary bundle burials and commingled deposits abound.

### Features 1 and 2

Features 1 and 2 at LS-3, Operation 3, were excavated in 1992 by Luis Sánchez Herrera and Adrián Badilla Cambronero. Feature 1 was a rectangular or oval-shaped pit cut into the bedrock (measuring  $1.5 \times 2$  m, and reaching a maximum depth of 1.1 m) that was used for the burial of human remains (Sánchez Herrera 1995). This feature had been disturbed, both in pre-Columbian times by the placement of Feature 2,

and more recently by two looters' pits. Feature 1, interpreted as the first burial, contained a cluster of disarticulated human skeletal remains that extended uninterrupted to the base of the intrusive Feature 2. Human collagen samples from this disarticulated cluster provided radiocarbon dates averaging over 150 years earlier than samples from intact bundle burials in Feature 2 (see Table 1).

Commingled remains recovered from Feature 1 most likely belong to original occupants of this grave that were disturbed during the burial of individuals in Feature 2; however, this could not be confirmed. Thus, both features are regarded as a single context for osteological analysis and minimum number of individuals (MNI) calculation, which was estimated at 29 individuals (Table 2). Special cultural objects found dispersed with the human remains in Feature 1

**Table 1.** AMS radiocarbon dates of human remains from the oldest burial horizon at Cerro Juan Díaz

Lab no.	Sample Context	Element Sampled	Conventional Radiocarbon Age	Calibrated Date (95.4% CI)	Ceramic Phase
β-224778	F. 16 Cranium 1	Tooth (ULP1)	1880 ± 40 B.P.	A.D. 33–244	La Mula
β-224781	F. 2 Bundle 2-A	Tooth (ULM1)	1800 ± 40 B.P.	A.D. 129–352	La Mula
β-147880	F. 16 Cranium 14	Tooth (LRM1)	1780 ± 40 B.P.	A.D. 175–404	Tonosí
β-224779	F. 16 Cranium 11	Tooth (UM2, L&R)	1700 ± 40 B.P.	A.D. 247–425	Tonosí
β-224780	F. 2 Bundle 1	Tooth (LLM1)	1690 ± 40 B.P.	A.D. 247–529	Tonosí
β-552727	F. 2 Bundle 4 Cranium 1	Bone (R. femur)	1680 ± 30 B.P.	A.D. 255–433	Tonosí
β-147876	F. 2 Bundle 2	Tooth (ULM3)	1640 ± 40 B.P.	A.D. 263–543	Tonosí
β-224783	F. 2 Bundle 4 Cranium 2	Tooth (ULM3)	1620 ± 40 B.P.	A.D. 365–553	Tonosí
β-224784	F. 2 Bundle 5	Tooth (URM2)	1600 ± 40 B.P.	A.D. 406–565	Tonosí
β-224785	F. 2 Bundle 6	Tooth (ULM1)	1570 ± 40 B.P.	A.D. 418–577	Tonosí
β-224788	F. 2 Bundle 13	Tooth (LRM2)	1560 ± 40 B.P.	A.D. 421–588	Tonosí
β-147878	F. 94 Individual 36	Tooth (URP2)	1500 ± 40 B.P.	A.D. 436–648	Cubitá

Note: All dates were run by Beta Analytic, Inc. and calibrated with OxCal 4.4 using IntCal20.

**Table 2.** Age distribution of individuals from the early burial features at Cerro Juan Díaz

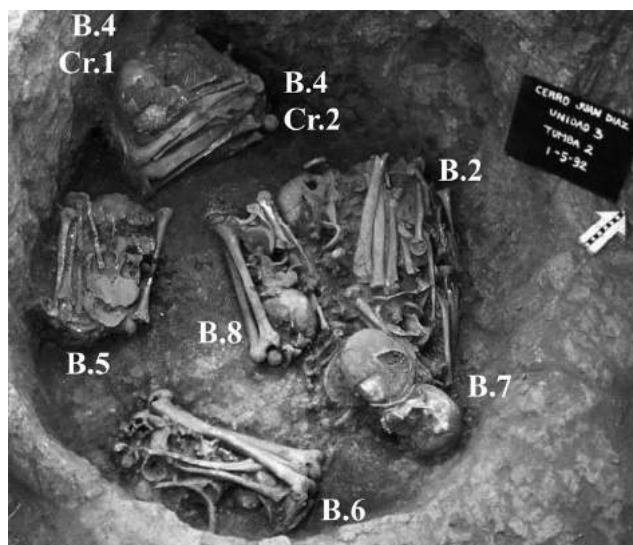
Feature	Non-adults			Adults				Total
	0–2 years	3–12 years	13–19 years	20–34 years	35–49 years	50+ years	Adult <sup>a</sup>	
1 & 2	3	4	4	2	3	5	8	29
16	2	10	1	0	3	2	1	19
94	0	1	0	0	1	0	2	4
Total	5	15	5	2	7	7	11	52

<sup>a</sup> Adult of indeterminate age.



comprised the following: two incense burners with strap handles (Espavé Rojo type), two hammered gold-copper plaques with convergent raised spirals belonging to Bray's Initial Group (A.D. 1–500) of Isthmian goldwork (Bray 1992), over 300 complete tubular thorny oyster (*Spondylus* spp.) shell beads ca. 4 cm long, and 24 complete jaguar (*Panthera onca*) and puma (*Puma concolor*) canine teeth with one or two holes drilled through the root for suspension (Sánchez Herrera 1995).

Feature 2 was a 2 m deep cylindrical pit with a bulbous base (1.3 m maximum diameter), containing human remains of varied burial modes and states of preservation. Several clearly defined bundle burials were placed along the west and south quadrants of the shaft. In most cases, these contained the remains of a single individual (i.e., Bundles 4, 5, 6, 8, 9, 10, and 13); the exception was a single primary, flexed burial of a 5–6-year-old child, which was placed directly above Bundle 4 (Fig. 3). This articulated child was denominated “Bundle 4 Cranium 1,” while the adult individual in the bundle below it was labeled “Bundle 4 Cranium 2.” Based on its articulated nature, this child must have been placed in the burial context soon after death, and thus, the maximum 2 $\sigma$  calibrated date range associated with this individual should, in turn, represent a maximum date for this intrusive burial event in general: cal A.D. 433 (Table 1). The remaining human remains in Feature 2 pertained to the aforementioned commingled cluster extending from Feature 1 through all strata of the north and east quadrants of Feature 2: Bundles 1, 2, 3, 7, 11, and 12.



**Figure 3.** Field photograph of the excavation of Feature 2, showing several bundle burials in situ. Note the primary burial of the non-adult skeleton “Bundle 4 Cranium 1” (a 5–6-year-old child) that was placed over the secondary burial of the adult skeleton “Bundle 4 Cranium 2” (a 35–45-year-old male), visible at the top of the photo.

Based on the contextual information from the field notebook of Sánchez Herrera (1992) at the time of excavation, as well as photographs and documentation from the excavation stored in the archaeology laboratories of the Smithsonian Tropical Research Institute, it appears that the following sequence of events occurred. The individuals originally buried in Feature 1 were laid to rest in the rectangular or oval-shaped burial cut, which was likely covered by a roof or awning based on the presence of posthole molds in the floor of this burial feature (Sánchez Herrera 1995). It is unknown if this original interment contained primary or secondary burials, nor how many individuals it contained. These original grave occupants were then disturbed when the burial cut for Feature 2 was made. Seven bundle burials were carefully arranged in Feature 2, and a recently deceased child placed on top of Bundle 4 (based on the articulated nature of Bundle 4 Cranium 1). Subsequently, the fill of the original burial was replaced in the grave, including the jumbled remains of the original occupants of Feature 1.

Sánchez Herrera recorded the following artifacts from within Feature 2: five polished circular agate beads (associated with Bundles 2, 7, 8, and 11) and one *Calliostoma* top snail shell with a perforation at its apex (with Bundle 1) (Sánchez Herrera 1995). Excavation photographs, field drawings, and lab-based inventories, as well as a subsequent publication, also report the presence of five perforated jaguar (*Panthera onca*) canines and one perforated puma (*Puma concolor*) canine associated with Bundle 2. In addition, 41 tubular and elongated *Spondylus* shell beads (ca. 4 cm long) were found associated with Bundles 1, 2, 4, 5, 6, 7, 9, and 10, as well as another Initial Style hammered gold-copper plaque with raised spirals between Bundle 2 and the northern wall of the burial cut (Cooke et al. 1998).

#### Feature 16

Located just a few meters north of Features 1 and 2, Feature 16 was excavated in 1993 by Luis Sánchez Herrera and Aguinaldo Pérez Yancky. This feature constituted a similar secondary burial context that disturbed an earlier grave, and consequently led to the commingling of the newly placed remains with the original occupants of the earlier burial context (Feature 26). In this case, however, all of the skeletal elements were characterized by disarticulated and commingled remains in a dense cluster (ca. 1 m<sup>3</sup>; Fig. 4), leading Sánchez Herrera and Pérez Yancky to enumerate individuals by cranium rather than bundle or skeleton. Nonetheless, a pattern similar to that of Features 1 and 2 emerged, with more

commingling and disorder of the remains recovered from the superficial aspect of the cluster, and more organized bundles found at its base. Radiocarbon dates also followed this pattern, with an early date for Cranium 1 at the top of the cluster, and a date nearly 200 years later in time for Cranium 14, found in an organized bundle burial in the lower layer. At least 19 individuals appear to be represented in this burial feature.

Many shell ornaments were found with the human remains in Feature 16. These include 33 *Spondylus* pendants associated with Cranium 4, five tear-shaped *Spondylus* beads placed near Cranium 12, 87 tubular beads and 30 zoomorphic beads made of *Spondylus* associated with Cranium 8, 120 thin tubular beads, one “medallion” bead, three rectangular beads, and 10 zoomorphic beads made of *Spondylus* near Cranium 7, and 15 pearls found near Cranium 11. Yet, the most spectacular artifacts, which have been featured in several publications over the last two decades, were found at the bottom of the grave in association with Cranium 14 (Cooke 2004; Cooke and Sánchez Herrera 1997; Cooke et al. 1998; Cooke et al. 2003). These included a copper ring tied with cotton string, 31 dog-shaped *Spondylus* pendants, two polished stone bars, perforated longitudinally (one is agate and the other an unidentified blue stone), and 74 perforated mammal—primarily puma, ocelot (*Leopardus pardalis*), and raccoon (*Procyon lotor*)—teeth (Cooke et al. 1998).

#### Feature 94

Feature 94 was excavated in 1995 by Ilean Isaza Aizpurúa and Aguilaro Pérez Yancky. The main occupant of this feature (Individual 36, a 40–55-year-old

probable male) was found in a primary, supine position with the legs and arms flexed along the right side of the body (Fig. 5). This primary burial was interpreted to have disturbed the original burial, denominated “Individual 38,” whose elements appear to represent at least three individuals and were found disturbed and dispersed after removal of Individual 36. Thus, following the pattern of the previous two burial contexts, Feature 94 seems to represent another burial that was reutilized in antiquity. Individual 36 was associated with a shell ornament shaped like long-tailed frog, three broken ceramic vessels, and a broken legged metate that contained maize starch grains imbedded on its work surface (Cooke and Sánchez Herrera 1997; Cooke et al. 1998; Cooke et al. 2000; Piperno and Holst 1998). A radiocarbon date from the dental collagen of Individual 36 places this individual at cal A.D. 436–648.

#### Materials and Methods

The human remains from each of these four burial features were reassembled from fragments and analyzed according to the North American Standards for osteological assessment (Buikstra and Ubelaker 1994). In an effort to reassociate the remains of individual skeletons from the highly commingled multiple burials of Features 2 and 16, cranial elements were matched with their postcranial counterparts by multiple means. During the excavation of both of these features, many of the bones were numbered and drawn prior to removal; however, this was done somewhat sporadically for Features 1 and 2, where many bones



**Figure 4.** Field photograph of the excavation of Feature 16 as viewed from the south, showing the depth and volume of the commingled human remains.



**Figure 5.** Field photograph of Individual 36 (a 40–55-year-old probable male) within Feature 94 from above.

from the uppermost and lowermost phases were not numbered, nor their specific locations plotted. The adult bone matching was based on pelvic sex and age, bone number proximity (i.e., how close one element was placed relative to another), and morphological and metric characteristics of the long bones. The non-adult bone matching was done similarly based on morphology and metric age of long bones, as well as catalog number proximity. Most of the bones of the thorax, as well as hand and foot bones, could not be reliably matched to individuals in these commingled contexts and, thus, were analyzed in isolation.

The MNI for each context was estimated based on a tally of the presence and completeness of each skeletal element per individual, and combined with separate tallies for commingled elements separated by non-adult and adult age categories. Completeness was coded as follows: 1 - > 75% complete, 2 - 25%–75% complete, and 3 - < 25% complete. For long bones, presence and completeness were recorded for both proximal and distal epiphyses, as well as proximal, middle, and distal thirds of the diaphyses. These inventory data on presence and completeness of skeletal elements were recorded initially in the Smithsonian Institution's Osteoware software ([osteoware.si.edu](http://osteoware.si.edu)), and subsequently organized in a Microsoft Excel workbook for MNI calculation (Table S1).

Preliminary age and sex estimations of the human remains from the early burials at Cerro Juan Díaz published in earlier works were made either by archaeologists in the field or during preliminary cleaning and organizing of the bones in the laboratory by Claudia Díaz. The present osteological analysis utilized this previous information as a starting point, but did not always agree with these earlier estimations. In the present study, non-adult age estimations were made based primarily on dental development (AlQahtani et al. 2010), but long bone lengths (Maresh 1970) and epiphyseal fusion (Schaefer et al. 2009) were utilized in cases lacking observable dentition. Adult age estimations were based primarily on pelvic morphological changes (Brooks and Suchey 1990; Lovejoy et al. 1985) and occasionally based on cranial suture closure (Meindl and Lovejoy 1985) in the absence of observable pelvises. Sex was estimated in older adolescents (aged 15–19 years at death) and adults based primarily on pelvic morphology (Buikstra and Ubelaker 1994; Phenice 1969), and secondarily on cranial morphology (Acsádi and Nemeskéri 1970).

Each individual was assessed macroscopically for the presence of dental and osseous pathologies following the standards recommended by Buikstra and Ubelaker (1994) to provide comprehensive descriptions of lesions from which specific differential diagnoses could be made. The following dental pathologies were

recorded: carious lesions, dental abscesses, enamel hypoplasias, and dental anomalies. Carious lesions were recorded for any area of decayed tooth enamel resulting in the complete perforation of enamel to the underlying dentin or pulp chamber. Aspect and surface location affected by each lesion and its degree of severity were recorded following the numerical coding system outlined in the above referenced standards. Abscesses perforating the alveolar bone adjacent to a tooth root were recorded by tooth affected and location of pus drainage. Enamel hypoplasias were recorded for each tooth based on the type of defect, including pits, grooves, and opacities, but were only noted to affect deciduous teeth in the present sample. Often, heavy dental calculus obscured the labial surfaces of the anterior teeth in the permanent dentition and limited the observability of these teeth for the presence of enamel hypoplasias. Dental anomalies were not surveyed in a systematic manner, but were noted during dental inventory on a case-by-case basis. Thus, these anomalies are likely underreported in the sample studied (see Smith-Guzmán 2021 for a multisite survey of dental and skeletal anomalies regionally).

Osseous pathologies were assessed by side, aspect, and section of the skeletal element affected according to five basic categories: abnormal bone formation, bone loss, porous lesions, trauma, and arthritis. Arthritis is not discussed in the present manuscript due to its association with the age of the individual (i.e., degenerative joint disease) in this population. The only form of abnormal bone formation found on the skeletal elements studied comprised periosteal reaction of the long bones, which was recorded based on reaction type, surface appearance, active or healing state, and any endosteal tissue involvement. Instances of bone loss, or lytic lesions, were recorded by location in terms of the number of foci, their dimensions, localized bony response, and the presence or absence of associated cortical thinning. Porous lesions appearing in the cranium were recorded separately, noting aspects of location affected, pore size, density of porosity, activity, and the presence of diploic expansion. Finally, instances of trauma represented by antemortem or perimortem fractures were assessed based on fracture type and characteristics, as well as the extent of callus formation.

Specific osseous and dental indications of cultural activities were assessed for those biocultural markers known to affect pre-Columbian populations in central Panama. These included artificial cranial modifications (Stewart 1958), for which the category (i.e., tabular or circumferential), degree of modification, center of pressure and its angle to the Frankfurt plane, and the presence of pad impressions were recorded. The presence of external auditory exostoses



was assessed separately for each intact auditory canal, and the degree of stenosis recorded in the case of exostosis presence (Smith-Guzmán and Cooke 2018a). Finally, the maxillary anterior teeth were assessed for lingual surface attrition of the maxillary anterior teeth (LSAMAT; Irish and Turner 1987), the presence of which was defined by wear facets of varied severity that appeared on the lingual surface of the maxillary incisors and canine teeth that were worn to a greater degree than the occlusal attrition seen on the other teeth within the same individual's dentition (Turner and Machado 1983).

## Results and Discussion

### Paleodemography

The proportions of the different age and sex groups present from the individuals buried in the earliest contexts at Cerro Juan Díaz generally follow an expected mortality curve for a preindustrial society, with higher numbers of young children and older adults represented in the graves than adolescents and young adults (Lewis 2006). Of the 52 individuals recovered from these burial contexts, 10% were infants aged 0–2 years, 29% children aged 3–12 years, 10% adolescents aged 13–19 years, 4% young adults aged 20–34 years, 13% middle adults aged 35–49 years, and 13% older adults aged 50 years or older, with the remaining 21% pertaining to adults of indeterminate age (Table 2).

That nearly half of the individuals buried in the early contexts at Cerro Juan Díaz correspond to infants, children, and adolescents follows closely the distribution of non-adults and adults seen in later contexts at the site (Díaz 1999). The older adolescent (15–19 years) and adult sample contained slightly more males (39%) than females (32%), and 29% of indeterminate sex (Table 3). Interestingly, the adult

female individuals present in the early burial contexts all pertained to the older (50+ years) age category, while there were three female adolescents present and two female individuals of indeterminate age. In contrast, males present included individuals in all age categories, but most corresponded to middle adults. Data on exact age and sex estimations made for each individual are accessible in Table S2.

The difference in age distribution by sex was significant when excluding individuals of indeterminate sex ( $\chi^2 = 13.21$ ,  $df = 4$ ,  $p = 0.010$ ). Caution must be taken in interpreting this result based on the small sample size of female and male individuals of estimated sex ( $n = 22$ ), and considering that the nine adult individuals of indeterminate sex could potentially fill in the gaps to make this sex-based age distribution more homogeneous. Nevertheless, this distribution suggests that females had a significantly lower risk of death between the ages of 20 and 50 years than males. One possible interpretation of this difference is that males were engaging in riskier activities during young and middle adulthood, such as participating in warfare.

Alternatively, male members of society may have simply been more likely to come into contact with dangerous wildlife (i.e., venomous snakes, crocodiles, felines, sharks, and stingrays) while hunting or foraging for resources. That ancient peoples of Panama often came into contact with and revered these dangerous animals is apparent by their frequent detailed depiction on painted ceramics and ornaments of various media and the use of their teeth and barbs as adornments (Linares 1977). In terms of the older adolescent sex ratio seen in the early Cerro Juan Díaz burials, this follows the pattern reported at the nearby site of Playa Venado, where the elevated frequency of adolescent female deaths was hypothesized to relate to obstetrical causes (Smith-Guzmán and Cooke 2018b).

**Table 3.** Sex distribution of older adolescents and adults from the early burial features at Cerro Juan Díaz<sup>a</sup>

Feature	15–19 years			20–34 years			35–49 years			50+ years			Adult <sup>b</sup>			Total		
	F	M	I	F	M	I	F	M	I	F	M	I	F	M	I	F	M	I
1 & 2	3	0	0	0	2	0	0	3	0	3	2	0	1	0	7	7	7	7
16	0	1	0	0	0	0	0	3	0	2	0	0	0	0	1	2	4	1
94	0	0	0	0	0	0	0	1	0	0	0	0	1	0	1	1	1	1
Total	3	1	0	0	2	0	0	7	0	5	2	0	2	0	9	10	12	9

<sup>a</sup> F, female; M, male; I, adult of indeterminate sex.

<sup>b</sup> Adult of indeterminate age.



### Changing interpretations

New age and sex estimations allow for different interpretations of several burials, including those of individuals previously interpreted as ritual practitioners. These instances signal that caution must be taken when making interpretations regarding occupation or biological sex of individuals on the basis of grave goods, particularly when made in the field or prior to osteological analysis.

Two individuals in Feature 16 were found associated with a copper ornament, and were originally interpreted as the remains of one adult and one infant (Cooke et al. 1998), or alternatively as one adult and one adolescent (Cooke 2004). The present study interprets the principal individual (Cranium 14) as a 6–7-year-old child whose direct association with the copper ornament found in this bundle context is made clear by the green-colored cupric staining visible on the right maxillary deciduous canine, left mandibular permanent lateral incisor, and the anterior bodies of several cervical vertebrae. The second individual (Cranium 11) is consistent with a 5–6-year-old child.

In the published literature, the diverse artifact assemblage found in association with these two individuals is interpreted as the belongings of a ritual specialist (i.e., a shaman or healer) and his apprentice (Cooke 1998a; Cooke 2004; Cooke et al. 2003; Cooke et al. 2007). However, this interpretation must be revised in light of the osteological analysis of these skeletons. Rather than a shaman and his apprentice, the accumulation of specialty or sumptuary goods with these two children more likely reflects a common trend in the mortuary archaeology of the region, in which precious goods are placed in funerary contexts with regard to age rather than social status (Briggs 1989, 1993). Although the social impetus behind this behavior is unclear, it is likely tied to a spiritual belief in an afterlife in which these mortuary offerings might be required especially for these immature members of society. Zoomorphic pendants and ornaments made from the teeth of animals may have represented the animal identifier of the individual's specific clan (Cooke 2004:281), or, alternatively, a mythical figure of regional religious significance (Stone 1963).

Similarly, the specialty items in Features 1 and 2 (including the three Initial Style gold ornaments) are reported in the published literature as belonging to an adult male individual considered to be the "principal occupant" of Feature 1 (Cooke et al. 2003), buried in a primary "flexed" (Cooke et al. 1998), or, alternatively, "extended" position (Cooke and Jiménez 2004). However, neither of these purported burial modes

are supported by the primary archaeological documentation nor can the demographical assessment be confirmed based on the osteological analysis reported herein. Based on the present analysis, the partial and commingled remains of at least three disarticulated individuals were present among the material excavated from Feature 1: a 16–21-year-old individual of probable male sex, a 5–6-year-old child, and an infant under one year of age. Due to the intrusion of Feature 2 upon Feature 1, the human remains and mortuary goods originally contained in Feature 1 were found jumbled and clustered together, extending from the limits of Feature 1 all the way to the base of Feature 2. While the notion that the artifacts found in association with this mass of commingled remains in Feature 1 represent the accoutrements of a ritual specialist (Cooke 2004) seems plausible, a clear association of these items with any one individual contained within this disturbed and commingled context is not possible. The reassessment of the association of sumptuary items with children in Feature 16 detailed above further signals that caution must be taken in assuming these items necessarily reveal the occupational status of individuals they were buried with, or indeed that they were placed with adults rather than immature individuals.

Another important demographical reinterpretation must be made regarding Individual 36, buried in Feature 94. This individual was originally thought to be a 20–25-year-old adult woman based on field observations (Cooke et al. 1998; Cooke et al. 2000); however, the present osteological assessment found that this individual is biologically consistent with a 40–55-year-old male individual. This change underlines the importance of careful osteological analysis even when associated artifacts are assumed "feminine" in nature (in this case, a metate used for grinding maize). During excavation, quick estimation of the biological sex of human remains is often made based primarily on the most visible morphological trait (i.e., the bony projection at the superciliary arches and glabella of the frontal bone). However, in the first author's experience, these cranial features are often misleadingly gracile in pre-Columbian Panamanian remains, particularly in individuals whose crania were artificially modified during life. A more holistic view, taking into account cranial features less affected by cranial modification (i.e., mastoid process size) and placing greater weight on pelvic morphology, provides a more accurate sex estimate. Accordingly, the Phenice traits of the pubis in Individual 36 of Feature 94 are overwhelmingly masculine, as is the size of the mastoid processes (see Fig. 10 below), while

other sexually dimorphic traits in this individual are more ambiguous.

Importantly, the in-depth osteological assessment of the human remains from Cerro Juan Díaz highlights some common issues in the excavation of mortuary contexts regionally. When possible, archaeologists should include specialists in bioarchaeology during the excavation of mortuary contexts for multiple reasons. Interpretations of these contexts are often formed during excavation and necessitate the participation of experts in human skeletal analysis. Likewise, many features of these mortuary contexts and skeletal elements visible in the field may be damaged or lost post-excavation, limiting the feasibility of retrospective analysis. Destructive sampling of human remains prior to osteological analysis should be avoided. In turn, bioarchaeologists should be aware of cultural and biological variants in the population, such as cranial modification, which may not be initially apparent in highly fragmented skeletal material, but which can affect morphological characteristics used in age and sex estimation.

Dental Pathology

A total of 575 permanent teeth from 41 individuals and 229 deciduous teeth from 19 non-adult individuals were observable (Table 4; raw data accessible in Table S3). Dental decay, including carious lesions and one dental abscess clearly associated with a large carious lesion, affected nine individuals (22%), including the deciduous teeth of three non-adult individuals. Ten individuals showed antemortem tooth loss (24%),

including nine adults and one non-adult. Four individuals (10%) showed signs of dental crowding, as evidenced by the overlap of two or more teeth within the dental arch. Dental crowding was rare in pre-modern times, but is thought to have been more prevalent in populations consuming a diet of soft or processed foods that do not produce the biomechanical masticatory stress necessary for the jaw bones to reach their full biological potential size (Corruccini 1990, 1991; Cramon-Taubadel 2011; Rose and Roblee 2009).

Numerous multidisciplinary studies over the last decades have identified key dietary staples in central Pacific Panama over 8,000 years prior to Spanish contact, including primarily marine and freshwater fish, white-tailed deer, and maize (Cooke 1998b; Cooke et al. 1996; Cooke et al. 2007; Cooke et al. 2008; Cooke et al. 2013; Dickau 2010; Jiménez and Cooke 2001; Piperno 2011). No known age- or sex-based dietary differences exist for Cerro Juan Díaz’s population; nevertheless, Norr (1991) observed a significant sex-based difference in stable isotope values of bone collagen from individuals buried at the nearby sites of Cerro Mangote and Sitio Sierra wherein females tended to have lower  $\delta^{15}\text{N}$  and  $\delta^{13}\text{C}$  values. A more recent study, which included six individuals from Cerro Juan Díaz, did not report a similar sex-based difference in dietary isotope values, but did find evidence for substantial fish and maize consumption at the site (Sharpe et al. 2021).

The dental pathologies and crowding in the early burials at Cerro Juan Díaz may reflect a diet high in soft, cariogenic foodstuffs. While maize is a common cariogenic cultigen, it is important to consider the cariogenic potential of other cultigens consumed

**Table 4.** Dental pathologies and cultural dental wear noted among the human remains from the early burials at Operation 3 of Cerro Juan Díaz

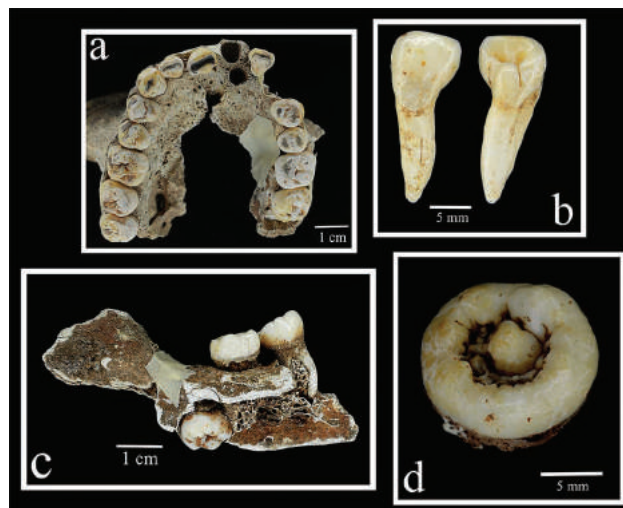
Dental Pathology	Primary Dentition		Secondary Dentition	
	Teeth affected (n/N)	Individuals affected (n/N)	Teeth affected (n/N)	Individuals affected (n/N)
Antemortem tooth loss	1/229	1/19	72/575	9/41
Caries	14/229	3/19	15/575	5/41
Abscess	–	1/19	–	1/41
Crowding	–	–	–	4/13
Enamel hypoplasia <sup>a</sup>	13/229	6/19	–	–
LSAMAT <sup>b</sup>	–	–	–	6/10

<sup>a</sup>Enamel hypoplasia included only defects to deciduous tooth enamel.  
<sup>b</sup>Lingual surface attrition of the maxillary anterior teeth.

widely in the lowlands of Pacific Panama in pre-Columbian times, including manioc (*Manihot esculenta*), squash (*Cucurbita moschata*), sweet potato (*Ipomoea batatas*), and several native tree fruits, like palms (*Bactris* spp., *Attalea butyracea*, and *Acrocomia aculeata*), nance (*Byrsonima crassifolia*), and zapote (family Sapotaceae) (Dickau 2010; Piperno 2011; Piperno and Holst 1998; Piperno et al. 2000). Comparatively, zapote (e.g., mamey) and nance contain more total sugars per 100 g serving (20.14 g and 8.31 g, respectively) than does corn (6.26 g) (US Department of Agriculture 2019).

Notably, 32% of non-adult individuals from the Cerro Juan Díaz early burials showed signs of developmental defects in the deciduous dental enamel, likely contributing to the proliferation of cariogenic pathogens (Duray 1990). This defective enamel manifested as dark, opaque discoloration (i.e., hypocalcification) or non-carious pitting of the labial enamel surfaces of the anterior deciduous teeth, tending to affect multiple teeth per individual. The maxillary deciduous central incisor was most commonly affected (7/16; 44%), followed by the maxillary deciduous lateral incisor (4/15; 27%) and the mandibular deciduous canine (2/23; 9%). These tooth crowns form and mineralize in utero or in early infancy; thus, these hypoplastic defects likely represent a response to nonspecific systemic physiological stress of the mother during gestation or of the infant in the early postnatal period, such as that caused by infectious disease or severe malnutrition (Blakey and Armelagos 1985; Goodman and Rose 1990; Ortner 2003:300–303). That the teeth affected tended to include both antimeres and often more than one tooth class per individual reduces the likelihood that these defects were caused by localized trauma to the tooth during development (Goodman and Rose 1990:64).

Three individuals recovered from bundle burials in Feature 2 had dental anomalies of permanent teeth (Fig. 6). A 35–45-year-old male individual (Cranium 2 from Bundle 4) displayed a supernumerary tooth socket just posterior to that of the maxillary left central incisor. Both the supernumerary tooth and the maxillary left central incisor were lost postmortem, and thus, the specific morphological characteristics of these teeth could not be observed. The maxillary left lateral incisor of the 15–17-year-old female individual recovered from nearby Bundle 5 showed a mild flexion of the long axis of the tooth root relative to that of the crown (cf. “mesial bending”; Edgar 2017; Edgar et al. 2016) accompanied by prominent interruption grooves along both mesial and distal marginal ridges, with the mesial groove extending halfway down the root. This individual’s maxillary left third premolar was rotated 90° toward



**Figure 6.** Examples of the dental anomalies present in the dentition of individuals from Cerro Juan Díaz Operation 3, Feature 2, including as follows: a) Occlusal view of the maxillary dentition from Bundle 4 Cranium 2 (35–45-year-old male) showing a supernumerary tooth socket posterior to the socket for the left central incisor, b) labial, lingual, and mesial views of the maxillary left lateral incisor from Bundle 5 (15–17-year-old female) showing mesial bending and interruption grooves, c) lingual view of the left side of the mandible from Bundle 13 (50+-year-old female) showing an embedded third molar facing inferiorly within the alveolar bone, d) occlusal oblique view of an isolated molar found at the bottom of Feature 2 characterized by supernumerary cusps including a central cusp, as well as non-caries pitting and cusplules.

the mesial aspect, such that the buccal surface faces mesially. The 50+-year-old female from Bundle 13 had an embedded mandibular left third molar that was inverted, with the occlusal surface of the crown facing inferiorly.

Finally, an isolated molar recovered from the bottom of Feature 2 that could not be associated confidently with any one individual shows an anomalous crown morphology characterized by a restricted occlusal aspect containing approximately 10 cusps surrounding a central cusp, which is separated by deep sulcus punctated by non-caries pits and minute enamel projections. A cautious differential diagnosis of this molar is underway, which considers both infectious and genetic factors as potential causative agents (Smith-Guzmán and Berger n.d.).

### Osseous Pathology

Many of the individuals buried in the oldest Cerro Juan Díaz graves showed skeletal signs of nonspecific physiological stress (Table 5). Systemic inflammation evidenced by periosteal reactions was present in 26% of individuals with observable postcranial elements, appearing bilaterally on the tibiae of four of the eight total individuals affected. The bilateral tibial

**Table 5.** Osseous pathologies and cultural modifications noted among the human remains from the early burials at Operation 3 of Cerro Juan Díaz

	Non-adults (< 15 years)	Adolescents and Adults (15+ years)			Total
		Female	Male	Indeterminate	
Periosteal reactions	4/10	1/8	1/10	2/3	8/31
Cranial porosity	6/14	0/9	1/12	0/1	7/36
External auditory exostosis	–	1/8	3/10	0/0	4/18
Artificial cranial modification	5/7	1/1	6/10	1/1	13/19

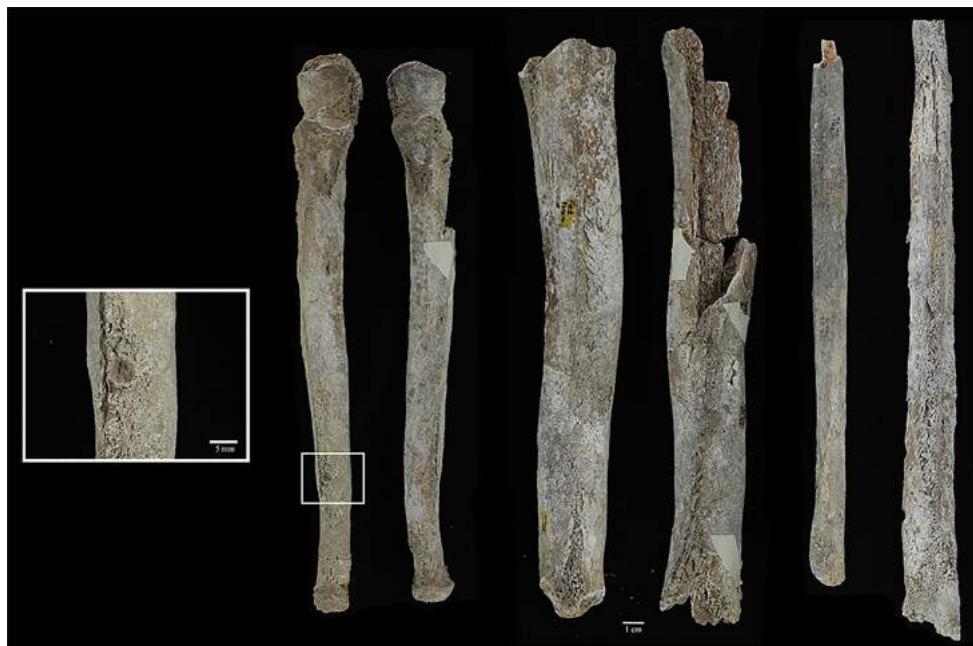periosteal reactions suggest a systemic physiological stressor, and have been considered by other authors among paleopathological indicators consistent with either yaws (*Treponema pallidum pertenue*) or syphilis (*Treponema pallidum pallidum*) in the population (Baker et al. 2020; Buikstra 2019; Hackett 1976; Harper et al. 2011). Other indicators compatible with treponemal disease in the population include anterior bowing (“sabre shin”), which was present in one isolated left tibia from the commingled remains in Feature 2, Bundle 2 (Fig. 7), as well as bilaterally in the tibiae from the 50+-year-old male from Feature 2, Bundle 10 (Fig. 8). The latter individual also showed enlarged diaphyses of the long bones affected and a circular superficial depressed lesion on the right ulna (Fig. 8, insert). This small superficial lesion ( $5.02 \times 4.49$  mm) perforated only the outer layers of the thickened cortex and was circumscribed with somewhat smooth, regular margins. No similar lesions were noted on this individual and the unifocal and small size of this lesion does not directly correspond to the larger or multifocal lytic postcranial lesions caused by the gumma of treponemal disease (Ortner 2003:286). Whatever the cause, it does appear likely that this lesion contained a nodular soft tissue component during life.

Cranial porosity indicative of a specific nutrient deficiency (e.g., scurvy) or anemia of infectious or noninfectious origin was present in 19% of observable crania, co-occurring significantly in many of the same individuals with periosteal reactions (Fisher’s exact,  $p = 0.046$ ). The majority of this cranial porosity consisted of cribra orbitalia (five of the seven individuals), as well as porosity observed on the hard palate in two individuals whose cranial bones were unobservable (see Table S2 for details). None of the porosity observed could be categorized as porotic hyperostosis. The only adult with cranial porosity manifested in this case by cribra orbitalia corresponded to the 50+-year-old male individual whose postcranial skeleton was severely affected by



**Figure 7.** Medial view of a left tibia (H.200) from the disarticulated and commingled cluster of human remains in Feature 2, Bundle 2, showing anterior bowing. This tibia could not be associated with a specific individual; thus, the age and sex are unknown.





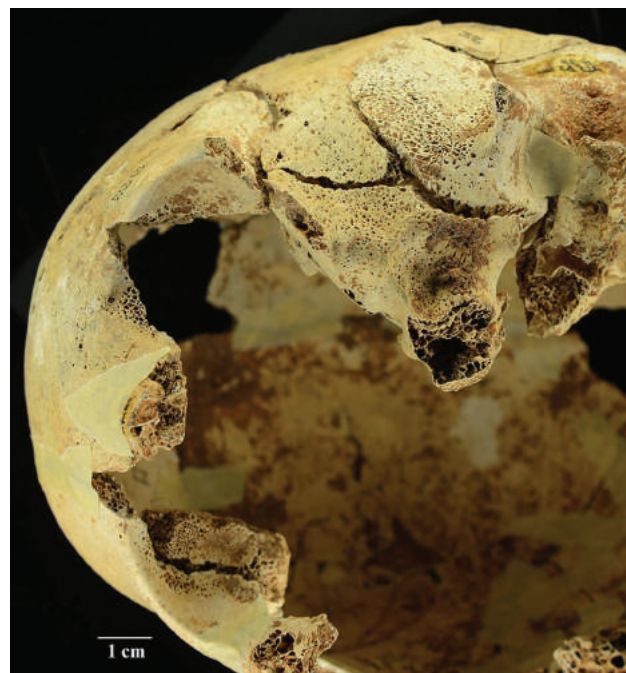
**Figure 8** Photographs of periosteal reactions on the ulnae (anterior view), tibiae (lateral view), and fibulae (medial view) from Feature 2, Bundle 10 (50+-year-old male), with inset showing a close-up view of the circular depressed lesion present on the anterior aspect of the distal third of the right ulna. Note the enlarged diaphysis of all bones affected (excluding the comparatively milder reactions on the right fibula), with slight anterior bowing and vascular impressions present on the tibiae.

periosteal reactions (Feature 2, Bundle 10; Fig. 8). The co-occurrence of these nonspecific stress markers suggests that the same systemic stressor may have been responsible for both pathologies in many of the individuals studied. This in turn supports the notion of cranial porosity due to infectious disease rather than from a dietary nutritional deficiency in these individuals (Fig. 9). The patterning of porous and periosteal lesions on the individuals studied was not diagnostic of scurvy specifically; nevertheless, the potential for malnutrition to have provoked porous cranial lesions cannot be ruled out.

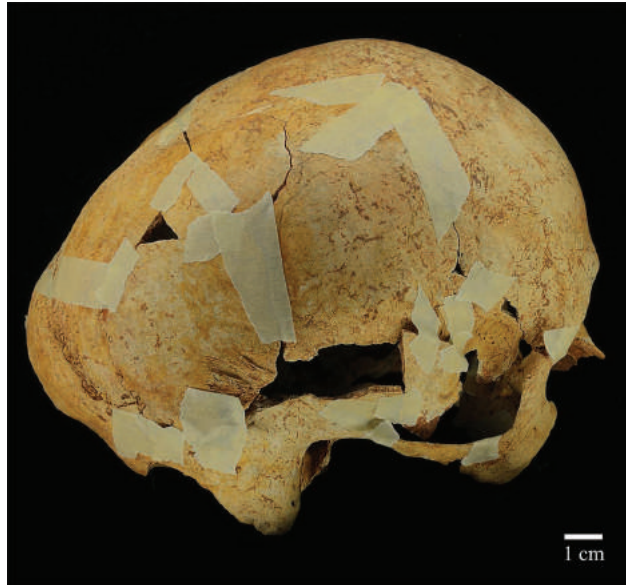### Evidence of Cultural Activities

Osteological evidence of cultural activities includes obelionic-type artificial cranial modification, which was present in 68% of observable crania (Table 5 and Fig. 10). Obelionic modification is characterized by superior flattening focused on the obelion, which in turn creates a broadened cranial shape with accentuated curvature of the occipital and frontal bones (Tiesler 2014). Crania modified in this form are distinguished from other tabular erect modifications by having an acute angle (typically  $< 50^\circ$ ) between the occipital squama and the Frankfurt Horizontal Plane when viewed from the lateral aspect (Nelson and Madimenos 2010). This cultural head-shaping

activity was practiced widely in the Greater Coclé cultural region of central Panama, likely as an embodied form of group identity (Díaz 1999; Stewart 1958). Unlike in other geographical regions of the



**Figure 9** Inferior oblique view of cranium (H.24) from Feature 2, Bundle 2-f (an 8-9-year-old child), showing severe porosity of the orbits, sphenoid, and left temporal bone.



**Figure 10.** Right lateral aspect of the cranium from Feature 94, Individual 36 (a 40–55-year-old probable male), showing superior flattening characteristic of obelionic-type artificial cranial modification.

precontact Americas (Tiesler 2014), no other forms of cranial modification appear to have been practiced by the inhabitants of Greater Coclé.

The method for achieving this distinct head shape has been debated in the literature. Some maintain that the absence of clear frontal or mandibular deformation excludes the possibility of a counter pressure point, instead suggesting a single focal point of applied pressure to the crown of the head. They suggest a cradleboard with an inclined endpiece as the most likely implement leading to the modification unintentionally (Stewart 1958; Tiesler 2014). However, others hold that such a cradleboard method would also flatten the occipital region, suggesting a method of flattening with head splints (Martínez de León Mármod 2009; Nelson and Madimenos 2010). The absence of any artifact or iconographic representations of the implement used to achieve obelionic modification leaves this debate unresolved for the time being.

Obelionic modification seldom appears at other sites in North and Central America, and in less than 30% of the population, postdating A.D. 500 where it does appear (Nelson and Madimenos 2010; Stewart 1939; Tiesler 2014). In Mexico, it is especially common at the site of El Zapotal in Veracruz (A.D. 600–900), being referred to as “Zapotal-type head shapes” (Romano 1974). Tiesler (2014) notes “superior flattening” has also been reported at frequencies up to 20% at Mayan Gulf Coast sites occupied during the second half of the first millennium A.D., and 29% in skulls at Chichén Itzá (ca. A.D. 900). In the Southwest

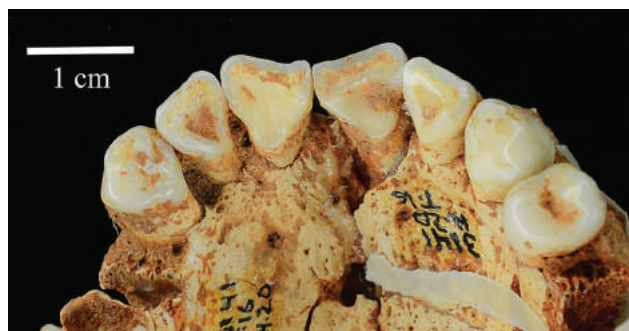
United States, this cranial modification was present in Pueblo populations (A.D. 900–1400), but in only 5% of crania studied (Nelson and Madimenos 2010).

The early burials at Cerro Juan Díaz (all predating A.D. 650) may represent the earliest widespread evidence of obelionic modification. The question of whether obelionic cranial modification was a practice more common and more ancient than in other parts of the New World awaits confirmation as this type of head shaping is often more subtle and may have been missed by bioarchaeologists working in regions with more extravagant head forms. Potential social status or kinship associations with cranial modification trends is a future avenue of research in Panamanian bioarchaeology to be accomplished through more in-depth studies focused on stable isotopes and biodistance analyses.

Three male individuals from Feature 2 and one female from Feature 16 showed external auditory exostoses, culminating in 21% of individuals with at least one auditory canal intact. The overall frequencies of external auditory exostoses by individual (only those with both auditory canals observable) among the early burials at Cerro Juan Díaz were found to be the highest (23.1%) when compared with four other sites along the Gulf of Panama (which ranged from 0%–12.5%), highlighting the importance of aquatic activities like diving for precious shells (Smith-Guzmán and Cooke 2018a). The fervent practice of shell diving during the oldest burial horizon at Cerro Juan Díaz is attested by the abundance of *Spondylus* and other marine shell ornaments within the early burials, whereas auditory exostoses were absent in individuals from burials at the site postdating A.D. 800 when gold likely took the place of marine shell as the most important commercial commodity (Cooke and Bray 1985; Martín-Rincón and Sánchez Herrera 2007; Sánchez Aguilar 2020). All three of the males affected also had obelionic-type modified crania while the female individual’s cranium was fragmented and unobservable for modification.

Sixty percent of individuals with observable anterior dentition showed signs of lingual surface attrition of the maxillary anterior teeth (LSAMAT; Table 4 and Fig. 11). LSAMAT was fairly evenly distributed across the different ages and sexes, affecting three of four observable adolescents (two females and one male), one older adult female (the only adult female with observable anterior teeth), and two of the four observable adult male individuals (both middle adults). This distinctive dental wear pattern has been noted among other pre-Columbian human remains from Panama and is thought to be evidence of the use of the upper front teeth as tools, perhaps in food preparation (e.g., peeling manioc) or in





**Figure 11.** Occlusal view of the anterior maxillary dentition from Feature 16, H.20 (a 30–45-year-old male), showing lingual surface attrition (LSAMAT). Note the flattened cingulum with associated wear facets on both central incisors.

basket-making activities (Irish and Turner 1987; Smith-Guzmán et al. 2018). This activity appears to have intensified over time at Cerro Juan Díaz, as LSAMAT was reported at a frequency of 80% of human remains from the later Operation 4 (ca. A.D. 800–1000) contexts at the site (Díaz 1999:65). In only one case (Feature 94, Individual 36) was related wear also present on the labial aspect of the anterior mandibular teeth.

Finally, it should be noted that none of the human skeletal remains showed signs of perimortem trauma, and there was only one instance of antemortem trauma. The latter comprised a healed compression fracture to the base of a first metatarsal from Feature 1, likely resulting from an accident. The absence of traumatic lesions in individuals from these early burials concords with that seen in the later contexts of Operation 4 at LS-3 (Cooke et al. 2003:137; Díaz 1999) and stands in apparent discord with contact period ethnohistorical and archaeological portrayals of Panama as rife with “endemic” warfare and with periodic mass human sacrifice events (Helms 1979; Ibarra Rojas 2012; Linares 1977; Lothrop 1954). Bioarchaeological evidence of these violent acts is likewise absent from nearby sites occupied around the same time period (Smith-Guzmán and Cooke 2018b).

## Conclusions

The osteological analysis of the human remains recovered from the oldest burial horizon at Cerro Juan Díaz has shifted the interpretations of these important features in several ways and has provided new insights into the health and cultural activities of the earliest inhabitants of the site. Specialty objects of metal and shell—frequently interpreted as symbols of rank and wealth alone—were more often associated with the remains of non-adults rather than adults

(following assertions by Briggs [1989]). Conceivably, this age-based association could signify that these valuable objects played a role in religious beliefs about life stages. Clearly, the complex relationship of specialty mortuary goods with interred individuals in central Pacific Panama extends beyond conventional interpretations of social status during life and merits future in-depth studies.

High rates of dental pathologies (relative to data from other pre-Columbian sites; Pezo Lanfranco and Eggers 2012) and dental crowding follow previous suggestions of high dietary maize content, and perhaps also reflect the consumption of sugary tree fruits. The skeletal evidence of an infectious disease consistent with treponematosi in this population, when taken with similar evidence from other nearby sites (Díaz 1999; Huard 2013; McGimsey et al. 1986–1987; Norr 1991; Smith-Guzmán and Cooke 2018b), suggests this disease was widespread in the region 1,000 years before Spanish arrival. Finally, biocultural stress markers present include high rates of head shaping and using teeth as tools that appear to be evenly distributed between the sexes. In contrast, aquatic activities causing external auditory exostoses are restricted to a small group of mostly men, suggesting that diving for marine shells used as ornaments was a male-dominated activity. No perimortem trauma was found on the bones, and the demography follows normal preindustrial patterns of life expectancy, suggesting normal attrition rather than mass casualty events. Future directions include the further study of human remains from the early burials through stable isotopes and biodistance analyses. Changes in health and cultural activities over time at the site will be assessed through the continued analysis of human remains from the later burial horizons at Cerro Juan Díaz.

## Acknowledgments

The authors would like to recognize the efforts of the excavation crews who helped Luis Sánchez Herrera and Adrián Badilla Cambronero clean and excavate these complex features at LS-3 between 1992 and 1995: Aguilaro Pérez (in Guna: Bailiver Sulup), Ilean Isaza Aizpurúa, Olman Solís, Javier Rodríguez, Luis Barriá (father and son), Píndaro Mitre, Melquiades Moreno, Yanilka Díaz, Juana Sánchez, and Gustavo Nelson Tapia. We owe special thanks to Claudia Díaz for initially preparing the human remains for study, as well as to Laura Schell, Vanessa Sánchez, and Leslie Naranjo for their assistance with the human remains analysis. The laboratory photographs of the human remains were taken by Raiza Segundo. The excavations at Cerro Juan Díaz were conducted with

the permission of the *Dirección Nacional del Patrimonio Histórico* of Panama with funding support from the National Geographic Society and the Smithsonian Institution (Scholarly Studies and Latino Initiatives grants). The human remains analysis by the first author was made possible through a postdoctoral fellowship funded by the Smithsonian Tropical Research Institute and additional research funding from the *Sistema Nacional de Investigación* (SNI) of the *Secretaría Nacional de Ciencia y Tecnología* (SENACYT) in Panama. Finally, we are grateful for the helpful comments and suggestions provided by two reviewers and an associate editor on an earlier version of this manuscript.

## References

- Acsádi, György, and János Nemeskéri. 1970. *History of Human Life Span and Mortality*. Akadémiai Kiadó, Budapest-Szeged.
- AlQahtani, Sakher J., Mark P. Hector, and Helen M. Liversidge. 2010. Brief communication: The London atlas of human tooth development and eruption. *American Journal of Physical Anthropology* 142(3):481–490. DOI: 10.1002/ajpa.21258.
- Baker, Brenda J., Gillian Crane-Kramer, Michael W. Dee, Lesley A. Gregoricka, Maciej Henneberg, Christine Lee, Sheila A. Lukehart, David C. Mabey, Charlotte A. Roberts, Ann L. W. Stodder, Anne C. Stone, and Stevie Winingear. 2020. Advancing the understanding of treponemal disease in the past and present. *American Journal of Physical Anthropology* 171(S70):5–41. DOI: 10.1002/ajpa.23988.
- Blakey, Michael L., and George J. Armelagos. 1985. Deciduous enamel defects in prehistoric Americans from Dickson Mounds: Prenatal and postnatal stress. *American Journal of Physical Anthropology* 66(4):371–380. DOI: 10.1002/ajpa.1330660404.
- Bray, Warwick. 1992. Sitio Conte metalwork in its pan-American context. In *River of Gold: Precolumbian Treasures from the Sitio Conte*, edited by Pamela Hearne and Robert J. Sharer. University of Pennsylvania Museum of Archaeology and Anthropology, Philadelphia, pp. 33–46.
- Briggs, Peter S. 1989. *Art, Death, and Social Order: The Mortuary Arts of Pre-Conquest Central Panama*. BAR International series, 550. British Archaeological Reports, Oxford.
- Briggs, Peter S. 1993. Fatal attractions: Interpretation of prehistoric mortuary remains from lower central America. In *Reinterpreting Prehistory of Central America*, edited by Mark Miller Graham. University Press of Colorado, Niwot, pp. 141–168.
- Brooks, Sheilagh, and Judy M. Suchey. 1990. Skeletal age determination based on the os pubis: A comparison of the Acsádi-Nemeskéri and Suchey-Brooks methods. *Human Evolution* 5(3):227–238.
- Buikstra, Jane E., ed. 2019. *Ortner's Identification of Pathological Conditions in Human Skeletal Remains*. 3rd ed. Academic Press, London.
- Buikstra, Jane E., and Douglas H. Ubelaker. 1994. *Standards for Data Collection from Human Skeletal Remains: Proceedings of a Seminar at the Field Museum of Natural History*. Arkansas Archeological Survey Research Series No. 44, Fayetteville.
- Carvajal, Diana Rocío, Claudia Patricia Díaz, Luis Alberto Sánchez Herrera, and Richard G. Cooke. 2006. ¿Fue cerro Juan Díaz, una aldea precolombina en el río La Villa, el pueblo de indios de Cubitá? In *Memorias Del VI Congreso Centroamericano de Historia, Panamá, 22–26 de Julio 2002*, edited by Yolanda Marco Serra and Marcela Camargo R. Universidad de Panamá, Panama City, pp. 100–123.
- Cooke, Richard G. 2004. Rich, poor, shaman, child: Animals, rank, and status in the “Gran Coclé” culture area of pre-Columbian Panamá. In *Behaviour Behind Bones: The Zooarchaeology of Ritual, Religion, Status and Identity*, edited by Sharyn Jones O'Day, Wim Van Neer, and Anton Ervynck. Oxbow Books, Oxford, pp. 271–284.
- Cooke, Richard G. 1998a. The felidae in pre-Columbian Panama: A thematic approach to their imagery and symbolism. In *Icons of Power: Feline Symbolism in the Americas*, edited by Nicholas J. Saunders. Routledge, London, pp. 77–121.
- Cooke, Richard G. 1998b. Subsistencia y economía casera de los indígenas precolombinos de Panamá. In *Antropología Panameña: Pueblos y Culturas*, edited by Aníbal Pastor Núñez. Editorial Universitaria, Panama City, pp. 61–134.
- Cooke, Richard G. 2011. The Gilcrease Collection and the Gran Coclé culture area of Panama: An assessment of provenience and chronology with comments on the iconography of pottery and metal-work. In *To Capture the Sun: Gold of Ancient Panama*. Gilcrease Museum, Tulsa, pp. 129–173.
- Cooke, Richard G., and Warwick Bray. 1985. The goldwork of Panama: An iconographic and chronological perspective. In *The Art of Precolumbian Gold: The Jan Mitchell Collection*, edited by Julie Jones. Weidenfeld and Nicolson, London, pp. 35–45.
- Cooke, Richard G., Ilean Isaza, John Griggs, Benoit Desjardins, and Luis A. Sánchez. 2003. Who crafted, exchanged and displayed gold in pre-Columbian Panama? In *Gold and Power in Ancient Costa Rica, Panama, and Colombia*, edited by Jeffrey Quilter and John W. Hoopes. Dumbarton Oaks, Washington, D.C., pp. 91–158.
- Cooke, Richard G., and Máximo Jiménez. 2004. Teasing out the species in diverse archaeofaunas: Is it worth the effort? An example from the tropical eastern Pacific. *Archaeofauna* 13:19–35.
- Cooke, Richard G., and Máximo Jiménez. 2008. Pre-Columbian use of freshwater fish in the Santa Maria biogeographical province, Panama. *Quaternary International* 185(1):46–58. DOI: 10.1016/j.quaint.2008.01.002.
- Cooke, Richard G., Máximo Jiménez, and Anthony J. Ranere. 2007. Influencia humanas sobre la vegetación y fauna de vertebrados de Panamá: Actualización de datos arqueozoológicos y su relación con el paisaje antrópico durante la Época Precolombina. In *Ecología y Evolución En Los Trópicos*, edited by Egbert Giles Leigh Jr., Edward Allen Herre, Jeremy B. C. Jackson, and Fernando Santos-Granero. Editora Novo Art, Panama, pp. 562–593.
- Cooke, Richard G., Máximo Jiménez, and Anthony J. Ranere. 2008. Archaeozoology, art, documents, and the life assemblage. In *Case Studies in Environmental Archaeology*, edited by Elizabeth J. Reitz, C. Margaret Scarry, and Sylvia J. Scudder. 2nd ed. Springer, New York. DOI: 10.1007/978-0-387-71303-8\_6.
- Cooke, Richard G., Lynette Norr, and Dolores R. Piperno. 1996. Native Americans and the Panamanian landscape: Harmony and discord between data sets appropriate for environmental history. In *Case Studies in Environmental Archaeology*, edited by Elizabeth J. Reitz, Lee A. Newsom, and Sylvia J. Scudder. Plenum Press, New York, pp. 103–126.



- Cooke, Richard G., Anthony Ranere, Georges Pearson, and Ruth Dickau. 2013. Radiocarbon chronology of early human settlement on the Isthmus of Panama (13,000–7000 BP) with comments on cultural affinities, environments, subsistence, and technological change. *Quaternary International* 301:3–22. DOI: 10.1016/j.quaint.2013.02.032.
- Cooke, Richard G., and Luis Alberto Sánchez Herrera. 1997. Coetaneidad de metalurgia, artesanías de concha y cerámica pintada en Cerro Juan Díaz, Gran Coclé, Panamá. *Boletín Museo del Oro (Colombia)* 42:57–85.
- Cooke, Richard G., Luis Alberto Sánchez Herrera, Ilean Isel Isaza Aizpurúa, and Aguilaro Pérez Yancky. 1998. Rasgos mortuarios y artefactos inusitados de Cerro Juan Díaz, una aldea precolombina del “Gran Coclé.” *La Antigua* 53:127–196.
- Cooke, Richard G., Luis Alberto Sánchez Herrera, and Koichi Udagawa. 2000. Contextualized goldwork from “Gran Coclé,” Panama: An update based on recent excavations and new radiocarbon dates for associated pottery styles. In *Precolumbian Gold: Technology, Style and Iconography*, edited by Colin McEwan. British Museum Press, London, pp. 154–176.
- Corruccini, Robert S. 1990. Australian aboriginal tooth succession, interproximal attrition, and Begg’s theory. *American Journal of Orthodontics and Dentofacial Orthopedics* 97(4):349–357. DOI: 10.1016/0889-5406(90)70107-N.
- Corruccini, Robert S. 1991. Anthropological aspects of orofacial and occlusal variations and anomalies. In *Advances in Dental Anthropology*, edited by M. A. Kelley and Clark S. Larsen. Wiley-Liss, New York, pp. 295–323.
- Cramon-Taubadel, Noreen von. 2011. Global human mandibular variation reflects differences in agricultural and hunter-gatherer subsistence strategies. *Proceedings of the National Academy of Sciences of the United States of America* 108(49):19546–19551. DOI: 10.1073/pnas.1113050108.
- Díaz, Claudia P. 1999. Estudio Bioantropológico de Rasgos Mortuarios de La “Operación 4” del Sitio Arqueológico Cerro Juan Díaz, Panamá Central. Licentiate thesis, Universidad de Los Andes, Bogotá.
- Dickau, Ruth. 2010. Microbotanical and macrobotanical evidence of plant use and the transition to agriculture in Panama. In *Integrating Zooarchaeology and Paleoethnobotany: A Consideration of Issues, Methods, and Cases*, edited by Amber M. Vanderwarker and Tanya M. Peres. Springer, New York, pp. 99–134. DOI: 10.1007/978-1-4419-0935-0.
- Duray, Stephen M. 1990. Deciduous enamel defects and caries susceptibility in a prehistoric Ohio population. *American Journal of Physical Anthropology* 81(1):27–34. DOI: 10.1002/ajpa.1330810105.
- Edgar, Heather J. H. 2017. *Dental Morphology for Anthropology: An Illustrated Manual*. Routledge, New York.
- Edgar, Heather J. H., Cathy Willermet, Corey S. Ragsdale, Alexis O’Donnell, and Shamsi Daneshvari. 2016. “Frequencies of Rare Incisor Variations Reflect Factors Influencing Precontact Population Relationships in Mexico and the American Southwest.” *International Journal of Osteoarchaeology* 26(6):987–1000. DOI:10.1002/oa.2510.
- Espinosa, Gaspar de. 1994. Relación de lo hecho por el licenciado Gaspar de Espinosa . . . que hiciese y cumpliese en el Viaje a las provincias de París y Natá y Cherú y a las otras comarcas. In *Indios y Negros En Panamá En Los Siglos XVI y XVII: Selecciones de Los Documentos Del Archivo General de Indias*, edited by Carol F. Jopling. Centro de Investigaciones Regionales de Mesoamérica, Antigua, Guatemala, pp. 61–74.
- Goodman, Alan H., and Jerome C. Rose. 1990. Assessment of systemic physiological perturbations from dental enamel hypoplasias and associated histological structures. *American Journal of Physical Anthropology* 33(S11):59–110. DOI: 10.1002/ajpa.1330330506.
- Hackett, Cecil J. 1976. *Diagnostic Criteria of Syphilis, Yaws and Treponarid (Treponematoses) and of Some Other Diseases in Dry Bones*. Springer, New York.
- Harper, Kristin N., Molly K. Zuckerman, Megan L. Harper, John D. Kingston, and George J. Armelagos. 2011. The origin and antiquity of syphilis revisited: An appraisal of Old World pre-Columbian evidence for treponemal infection. *American Journal of Physical Anthropology* 146(S53):99–133. DOI: 10.1002/ajpa.21613.
- Helms, Mary W. 1979. *Ancient Panama: Chiefs in Search of Power*. University of Texas Press, Austin.
- Huard, Aimee E. 2013. *Cerro Mangote: Interpretations of Space Based on Mortuary Analysis*. PhD dissertation, Binghamton University, Vestal, NY.
- Ibarra Rojas, Eugenia. 2012. Exploring warfare and prisoner capture in indigenous southern Central America. *Revista de Arqueología Americana* 30:105–131.
- Irish, Joel D., and Christy G. Turner II. 1987. More lingual surface attrition of the maxillary anterior teeth in American Indians: Prehistoric Panamanians. *American Journal of Physical Anthropology* 73(2):209–213. DOI: 10.1002/ajpa.1330730207.
- Isaza Aizpurúa, Ilean Isel. 2007. *The Ancestors of Parita: Pre-Columbian Settlement Patterns in the Lower La Villa River Valley, Azuero Peninsula, Panama*. PhD dissertation, Boston University, Boston.
- Isaza Aizpurúa, Ilean I. 2013. Diachronic developments of two Precolumbian settlements in the southern domains of Parita’s chiefdom, Gran Coclé, Panama. In *Multiscalar Approaches to Studying Social Organization and Change in the Isthmo-Colombian Area*, edited by Scott D. Palumbo, Ana María Boada Rivas, William A. Locascio, and Adam C. J. Menzies. Center for Comparative Archaeology. Pittsburgh.
- Jiménez, Máximo, and Richard G. Cooke. 2001. La pesca en el borde de un estuario neotropical: El caso de Cerro Juan Díaz (Bahía de Parita, Costa Del Pacífico de Panamá). *Noticias de Antropología y Arqueología: Especial NAYa* 1:1–29.
- Lewis, Mary E. 2006. Fragile bones and shallow graves. In *The Bioarchaeology of Children: Perspectives from Biological and Forensic Anthropology*, edited by Mary E. Lewis. Cambridge University Press, Cambridge, pp. 20–37.
- Linares, Olga F. 1977. *Ecology and the Arts in Ancient Panama: On the Development of Social Rank and Symbolism in the Central Provinces*. Studies in Pre-Columbian Art and Archaeology, No. 17. Dumbarton Oaks, Washington, D.C.
- Lothrop, Samuel K. 1954. Suicide, sacrifice and mutilations in burials at Venado Beach, Panama. *American Antiquity* 19(3):226–234. DOI: 10.2307/277128.
- Lovejoy, C. Owen, Richard S. Meindl, Thomas R. Pryzbeck, and Robert P. Mensforth. 1985. Chronological metamorphosis of the auricular surface of the ilium: A new method for the determination of adult skeletal age at death. *American Journal of Physical Anthropology* 68(1):15–28. DOI: 10.1002/ajpa.1330680103.
- Maresh, M. M. 1970. Measurements from roentgenograms. In *Human Growth and Development*, edited by Robert W. McCammon. Charles C. Thomas, Springfield, IL, pp. 157–200.
- Martín-Rincón, Juan Guillermo, and Luis A. Sánchez Herrera. 2007. El Istmo Mediterráneo: Intercambio, simbolismo y filiación social en la Bahía de Panamá durante el período 500–1000 DC. *Arqueología del Área Intermedia* 7:113–122.
- Martínez de León Mármol, Blanca Lilia. 2009. La deformación cefálica intencional tipo tabular, variante superior, en El

- Zapota, Veracruz. *Estudios de Antropología Biológica* 14(2):489–502.
- Martyr d'Anghera, Peter. 1912. *De Orbe Novo: The Eight Decades of Peter Martyr d'Anghera*, edited by Francis Augustus MacNutt. G.P. Putnam's Sons, New York.
- Mayo, Julia, and Richard G. Cooke. 2005. La industria prehispanica de conchas marinas en Gran Coclé, Panamá: Análisis tecnológico de los artefactos de concha del basurerotaller del Sitio Cerro Juan Díaz, Los Santos, Panamá. *Archaeofauna* 14:285–298.
- McGimsey, Charles R., III, Michael B. Collins, and Thomas W. McKern. 1986–1987. Cerro Mangote and its population. *Journal of the Steward Anthropological Society* 16(1–2):125–157.
- Meindl, Richard S., and C. Owen Lovejoy. 1985. Ectocranial suture closure: A revised method for the determination of skeletal age at death based on the lateral-anterior sutures. *American Journal of Physical Anthropology* 68(1):57–66. DOI: 10.1002/ajpa.1330680106.
- Nelson, Greg C., and Felicia C. Madimenos. 2010. Obelionic cranial deformation in the Puebloan Southwest. *American Journal of Physical Anthropology* 143(3):465–472. DOI: 10.1002/ajpa.21353.
- Norr, Lynette Caryl. 1991. *Nutritional Consequences of Prehistoric Subsistence Strategies in Lower Central America*. PhD dissertation, University of Illinois, Urbana-Champaign.
- Ortner, Donald J. 2003. *Identification of Pathological Conditions in Human Skeletal Remains*. 2nd ed. Academic Press, San Diego.
- Pezo Lanfranco, Luis, and Sabine Eggers. 2012. Caries through time: An anthropological overview. In *Contemporary Approach to Dental Caries*, edited by Ming-Yu Li. IntechOpen, London. DOI: 10.5772/38059.
- Phenice, Terrell W. 1969. A newly developed visual method of sexing the os pubis. *American Journal of Physical Anthropology* 30(2):297–301. DOI: 10.1002/ajpa.1330300214.
- Piperno, Dolores R. 2011. The origins of plant cultivation and domestication in the New World tropics: Patterns, process, and new developments. *Current Anthropology* 52(S4):53–70. DOI: 10.1086/659998.
- Piperno, Dolores R., and Irene Holst. 1998. The presence of starch grains on prehistoric stone tools from the humid neotropics: Indications of early tuber use and agriculture in Panama. *Journal of Archaeological Science* 25(8):765–776. DOI: 10.1006/jasc.1997.0258.
- Piperno, Dolores R., Anthony J. Ranere, Irene Holst, and Patricia Hansell. 2000. Starch grains reveal early root crop horticulture in the Panamanian tropical forest. *Nature* 407(6806):894–897. DOI: 10.1038/35038055.
- Romano, Arturo. 1974. Deformación cefálica intencional. In *Antropología Física, Época Prehispánica*, edited by Juan Comas Secretaría de Educación Pública—Instituto Nacional de Antropología e Historia, Mexico, pp. 197–227.
- Rose, Jerome C., and Richard D. Roblee. 2009. Origins of dental crowding and malocclusions: An anthropological perspective. *Compendium of Continuing Education in Dentistry* 30(5):292–300.
- Sánchez Aguilarte, Vanessa Valentina. 2020. *Utilizando la exostosis Del Oído Externo Para Rastrear Cambios Temporales En Actividades Acuáticas Humanas En el Panamá Precolombino*. Licentiate thesis, Universidad de Panamá, Panama City.
- Sánchez Herrera, Luis Alberto. 1992. Field notebook of Cerro Juan Díaz excavation, January 27–June 22, 1992. On file at the Smithsonian Tropical Research Institute, Panama City.
- Sánchez Herrera, Luis Alberto. 1995. *Análisis Estilístico de Dos Componentes Cerámicos de Cerro Juan Díaz: Su Relación Con El Surgimiento de Las Sociedades Cacicales En Panamá (400–700 d.C.)*. Licentiate thesis, Universidad de Costa Rica, San José.
- Schaefer, Maureen, Sue Black, and Louise Scheuer. 2009. *Juvenile Osteology: A Laboratory and Field Manual*. Academic Press, London.
- Sharpe, Ashley E., Nicole Smith-Guzmán, Jason Curtis, Ilean Isaza-Aizpurúa, George D. Kamenov, Thomas A. Wake, and Richard G. Cooke. 2021. A preliminary multi-isotope assessment of human mobility and diet in pre-Columbian Panama. *Journal of Archaeological Science: Reports* 36:102876. DOI: 10.1016/j.jasrep.2021.102876.
- Smith-Guzmán, Nicole E. 2021. An isthmus of isolation: The likely elevated prevalence of genetic disease in ancient Panama and implications for considering rare diseases in paleopathology. *International Journal of Paleopathology* 33:1–12. DOI: 10.1016/j.ijpp.2021.01.002.
- Smith-Guzmán, Nicole E., and Steph Berger. n.d. Genetic anomaly or congenital syphilis? Supernumerary occlusal cusps in a molar from a pre-Columbian burial at Cerro Juan Díaz, Panamá. Unpublished manuscript on file at the Smithsonian Tropical Research Institute, Panama City. Available upon request from SmithN@si.edu.
- Smith-Guzmán, Nicole E., and Richard G. Cooke. 2018a. Cold-water diving in the tropics? External auditory exostoses among the pre-Columbian inhabitants of Panama. *American Journal of Physical Anthropology* 168(3):448–458. DOI: 10.1002/ajpa.23757.
- Smith-Guzmán, Nicole E., and Richard G. Cooke. 2018b. Interpersonal violence at Playa Venado, Panama (550–850 AD): A reevaluation of the evidence. *Latin American Antiquity* 29(4):718–735. DOI: 10.1017/laq.2018.48.
- Smith-Guzmán, Nicole E., Jeffrey A. Toretzky, Jason Tsai, and Richard G. Cooke. 2018. A probable primary malignant bone tumor in a pre-Columbian human humerus from Cerro Brujo, Bocas del Toro, Panamá. *International Journal of Paleopathology* 21:138–146. DOI: 10.1016/j.ijpp.2017.05.005.
- Stewart, T. Dale. 1939. A new type of artificial cranial deformation from Florida. *Journal of the Washington Academy of Sciences* 29(10):460–465.
- Stewart, T. Dale. 1958. Skeletal remains from Venado Beach, Panama: cranial deformity. *Acts of the XXXIII Congreso Internacional de Americanistas, San Jose, 20–27 Julio 1958* 3:45–54.
- Stone, Doris. 1963. Cult traits in southeastern Costa Rica and their significance. *American Antiquity* 28(3):339–359. DOI: 10.2307/278277.
- Tiesler, Vera. 2014. *The Bioarchaeology of Artificial Cranial Modifications: New Approaches to Head Shaping and its Meanings in Pre-Columbian Mesoamerica and Beyond*. Springer, New York.
- Turner, Christy G., II, and Lilia M. Cheuiche Machado. 1983. A new dental wear pattern and evidence for high carbohydrate consumption in a Brazilian Archaic skeletal population. *American Journal of Physical Anthropology* 61(1):125–130. DOI: 10.1002/ajpa.1330610113.
- US Department of Agriculture, Agricultural Research Service. 2019. FoodData Central. <https://fdc.nal.usda.gov>. Accessed April 14, 2020.